NORMAL Intrauterine Pregnancy

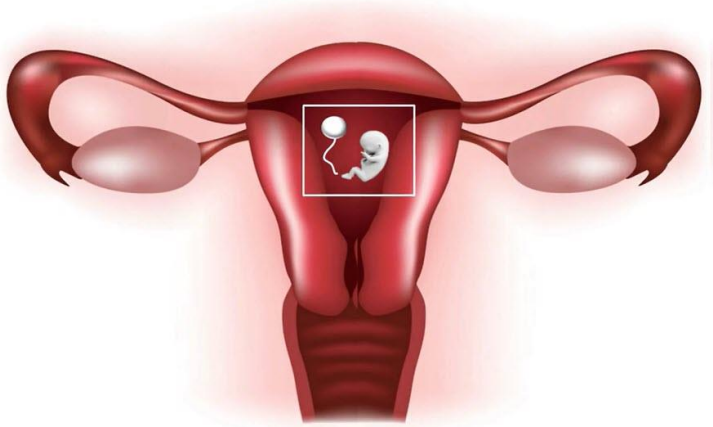

TRANSABDOMINAL VERSUS TRANSVAGINAL

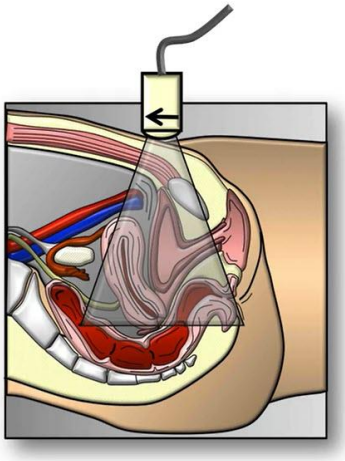

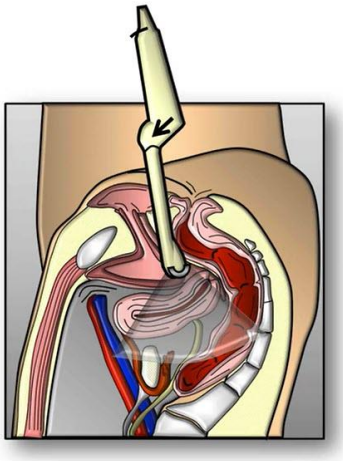

10

days earlier with transvaginal scanning

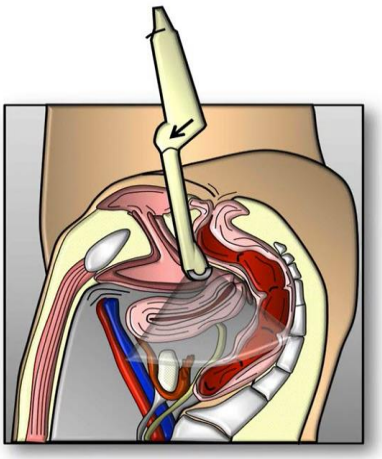

Gestational Sac

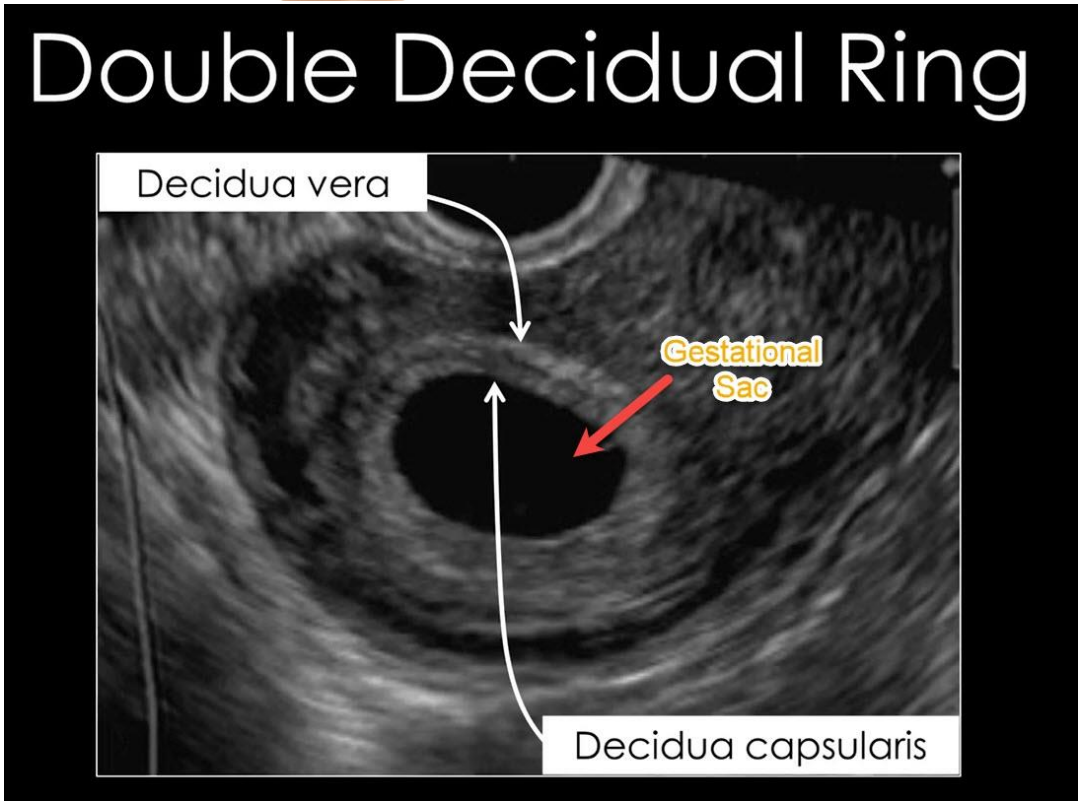

Yolk Sac

Yolk Sac

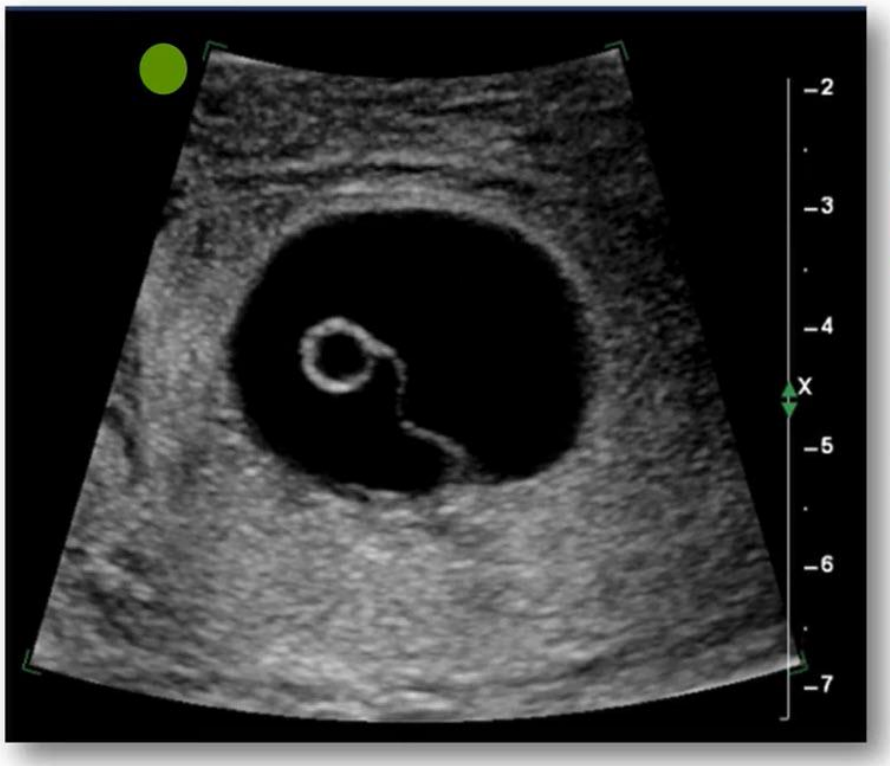

Yolk Sac

Seen at 5 to 6 weeks by *transvaginal* ultrasound

Disappears by end of first trimester

Yolk Sac = IUP

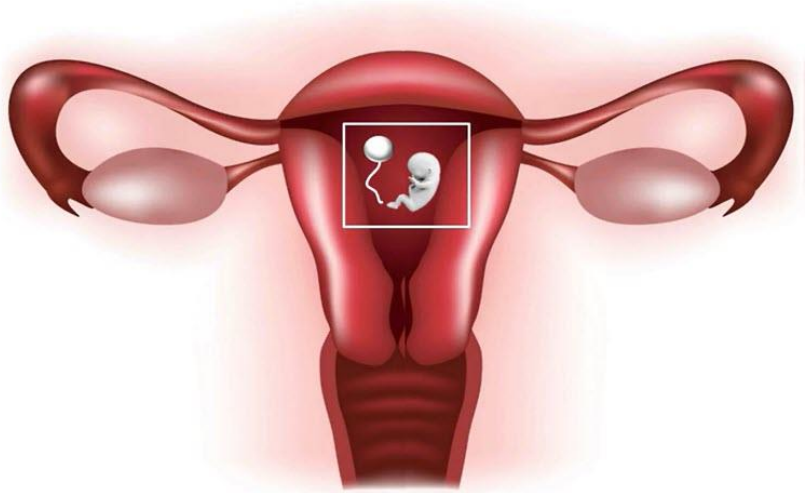

Yolk Sac

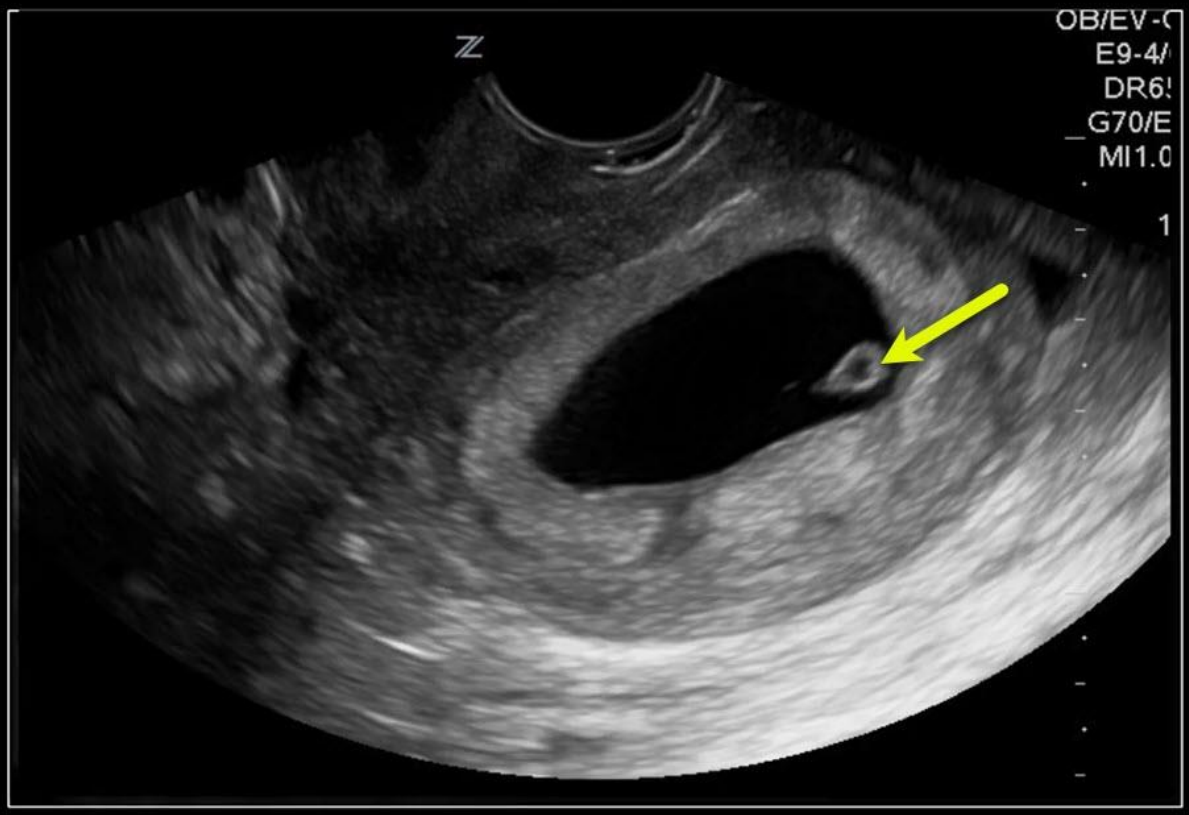

Fetal Pole

Fetal Pole

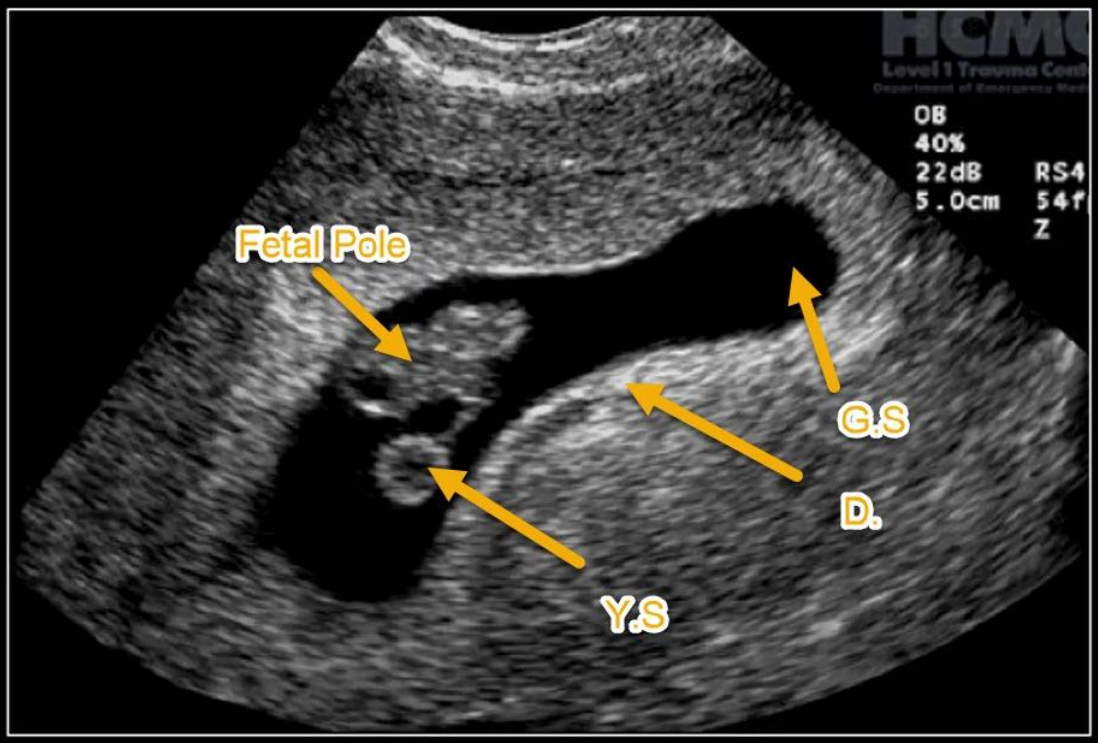

Fetal Heart Motion

FETAL HEART MOTION

Presence lowers incidence of spontaneous abortion to around 10%

FETAL HEART MOTION

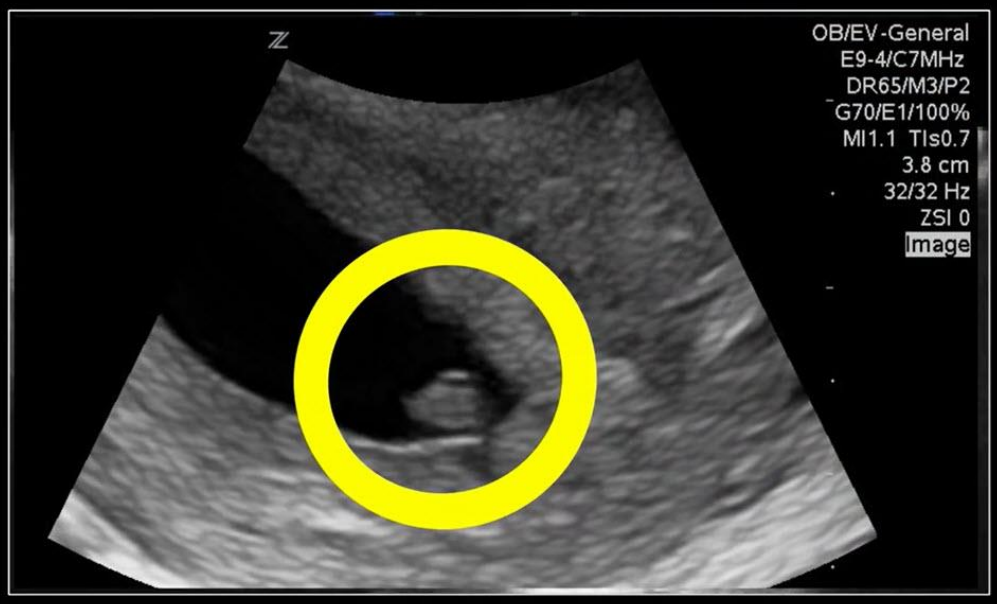

When will I see it?

STRUCTURE	TV	TA
GESTATIONAL SAC	4.5 weeks	6 weeks
YOLK SAC	5 - 6 weeks	6 – 7 weeks
FETAL POLE	6 – 7 weeks	7 - 8 weeks
FETAL HEART MOTION	7 weeks	8 weeks

What is a Pseudogestational Sac?

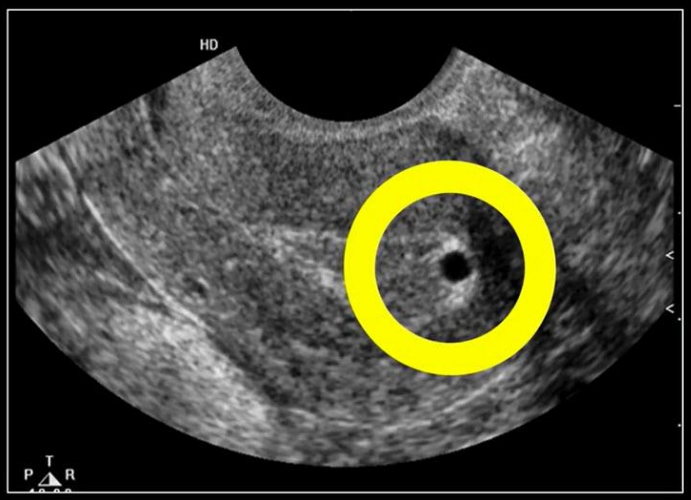

Pseudogestational Sac

SMALL

(less then 10mm)

RARE

(GS much more common)

GESTATIONAL DATING

Gestational Sac

Crown-to-Rump Length

GESTATIONAL AGE

Gestational Sac

grows 1mm / day

GESTATIONAL AGE =

Sac Diameter (mm)
+ 30 days

19 + 30 = 49 days
(7 weeks)

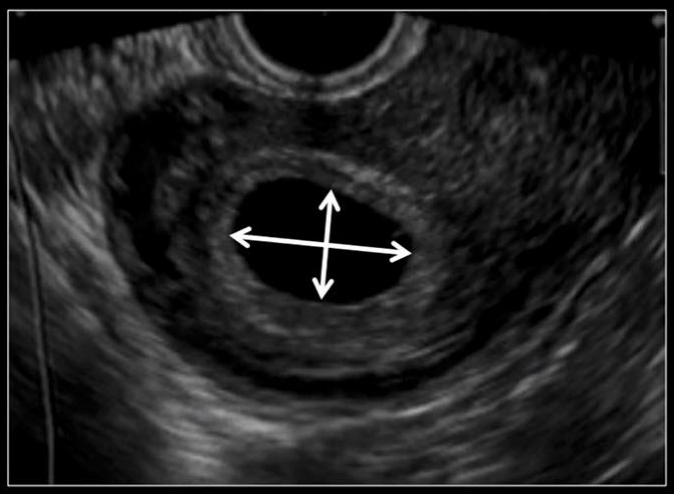

Does not include decidual ring.

CROWN-TO-RUMP

Most Accurate Measurement for Gestational Dating

CROWN-TO-RUMP

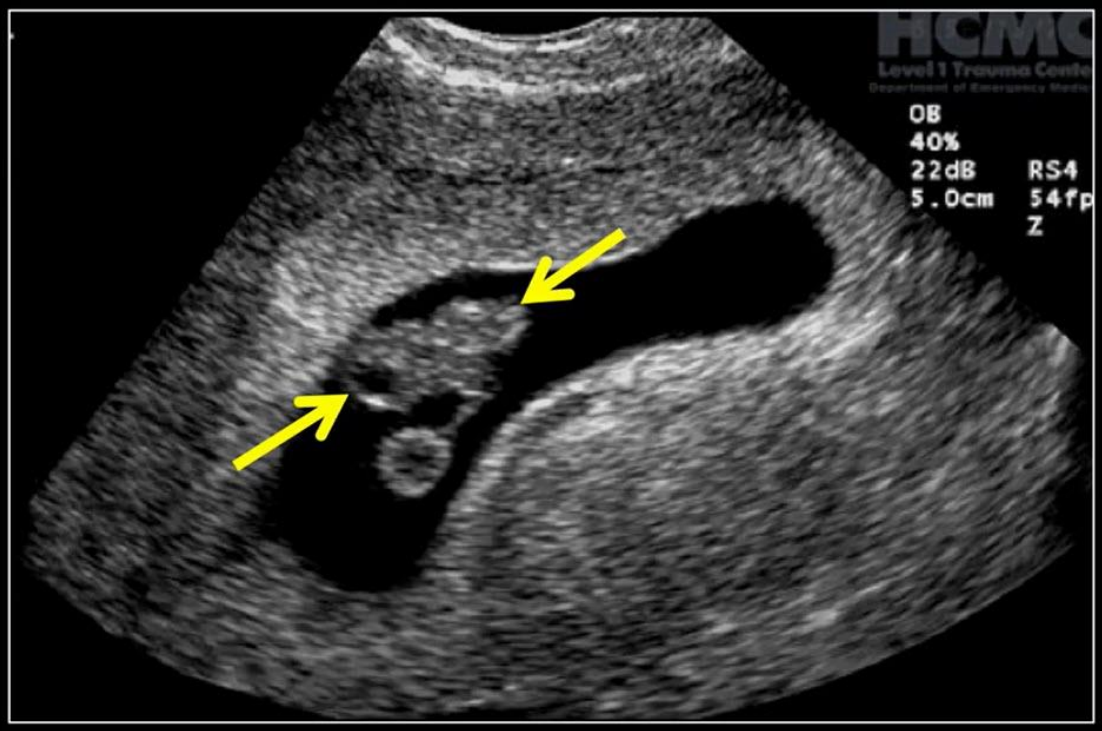

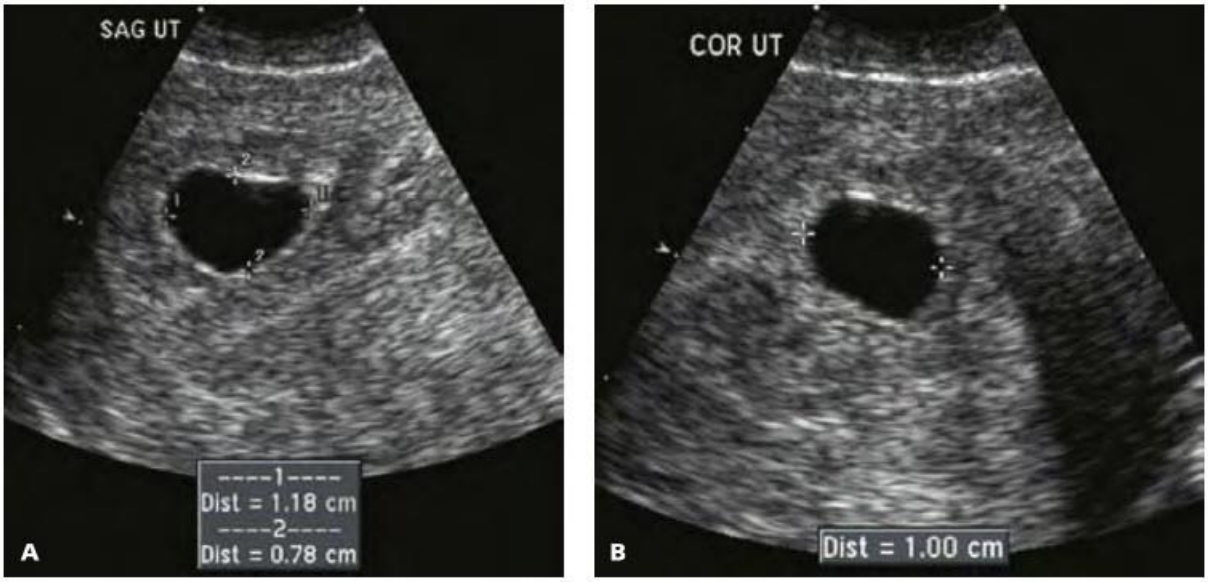

What is CRL?

CRL is the length of the foetus, measured from the top of its head to its buttocks. This measurement is in centimetres and doesn't take into consideration the limbs or the yolk sac. Since CRL can be taken from about 6 to 7 weeks of the pregnancy with an upper limit of 14 weeks, it is useful in calculating the gestational age of the foetus. The low biological variability at this stage of pregnancy makes it the most accurate estimation of your baby's gestational age.

Once the gestational age is evident from the CRL, your doctor can provide an estimated delivery date. The earlier this scan is conducted, the more accurate it is. Note that the gestational age is different from the fertilisation age. Gestational age is calculated from the first day of your last menstrual period, whereas fertilisation age is typically two weeks less than the gestational age.

Crown Rump Length Chart

The CRL diagram was first presented by Robinson in 1975 and is, still, the primary reference for pregnancy dating as well as evaluation. Below, we provide a CRL chart for your reference.

Gestational Age in Weeks	CRL (mm)	Mass
6 weeks	4 mm	< 1g
7 weeks	11 mm	< 1g
8 weeks	17 mm	1 g
9 weeks	23 mm	2 g
10 weeks	34 mm	4 g
11 weeks	44 mm	7 g
12 weeks	57 mm	14 g
13 weeks	68 mm	23 g
14 weeks	81 mm	43 g

These are the approximate foetus measurements at different stages of pregnancy. Other factors such as the mother's age, smoking habits, and the amount of folic acid consumed may influence these measurements.

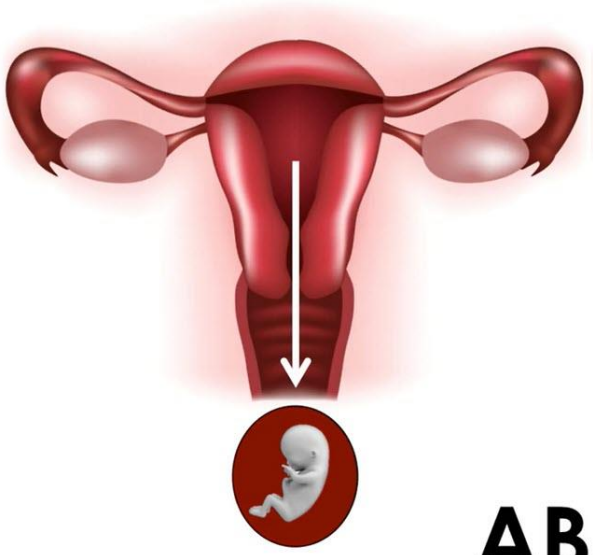

ABNORMAL

Intrauterine Pregnancy

1 in 3 pregnancies end in miscarriage

CAUSES
Maternal
Fetal
Placenta

ABORTION
Complete
Incomplete
Threatened
Missed
Inevitable
Septic

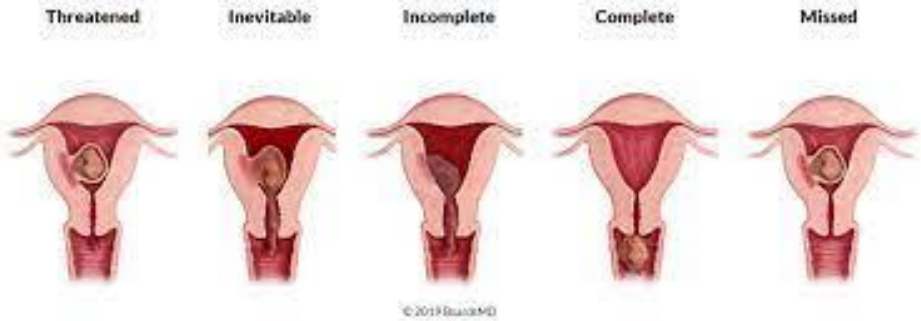

Types of Miscarriages

Missed
- No vaginal bleeding
- Closed cervical os
- No fetal cardiac activity or empty sac

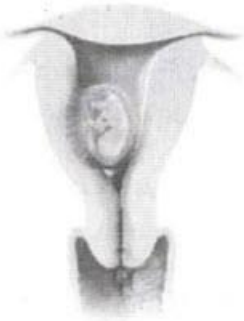

Threatened
- Vaginal bleeding
- Closed cervical os
- Fetal cardiac activity

Inevitable
- Vaginal bleeding
- Dilated cervical os
- Products of conception may be seen or felt at or above cervical os

Incomplete
- Vaginal bleeding
- Dilated cervical os
- Some products of conception expelled & some remain

Complete
- Vaginal bleeding
- Closed cervical os
- Products of conception completely expelled

Indicators of Failed IUP

Gestational
Sac = 20 mm

+

No Yolk Sac
Or Fetal Pole

Blighted
Ovum

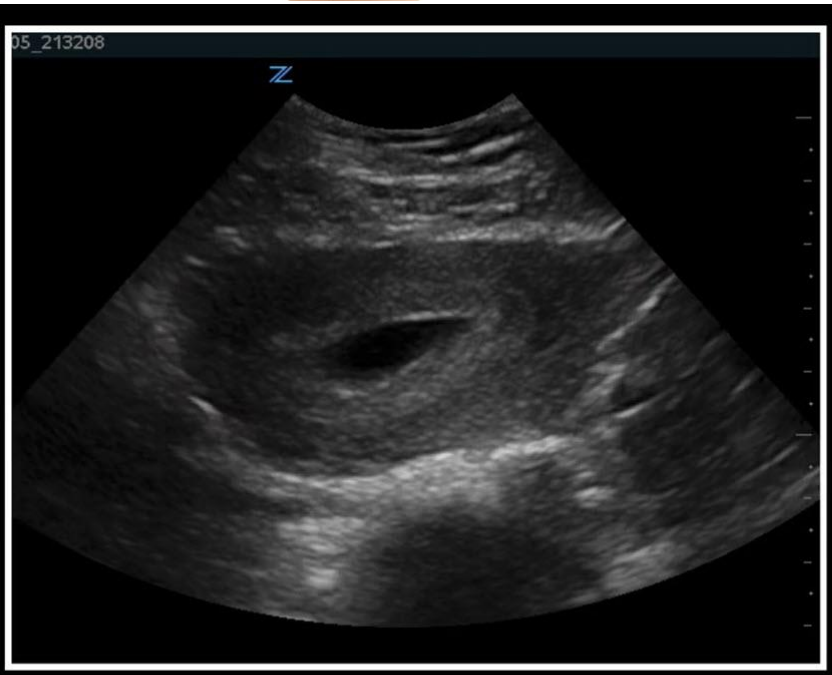

Blighted Ovum

SUBCHORIONIC HEMATOMA

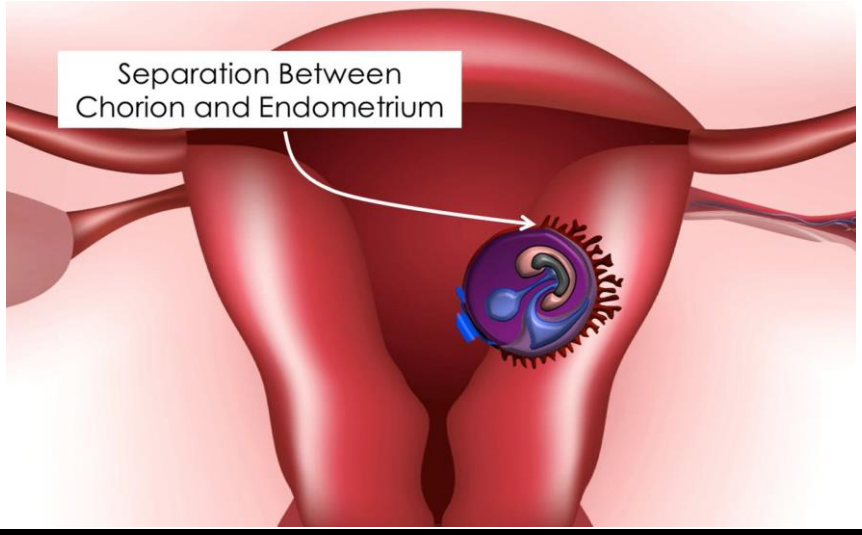

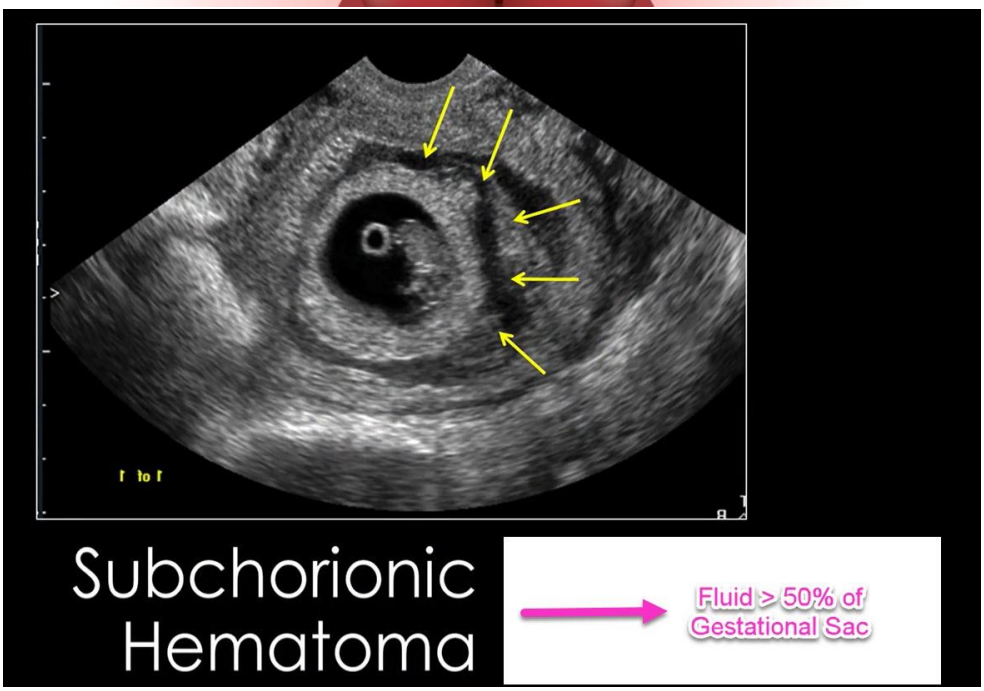

IUFD

Intrauterine
Fetal
Demise

7 weeks by CRL

No FHM

Intrauterine Mass

Hydatidiform mole	
Clinical presentation	• Abnormal vaginal bleeding ± hydropic tissue • Uterine enlargement > gestational age • Abnormally elevated β-hCG levels • Theca lutein ovarian cysts • Hyperemesis gravidarum • Preeclampsia with severe features • Hyperthyroidism
Risk factors	• Extremes of maternal age • History of hydatidiform mole
Diagnosis	• "Snowstorm" appearance on ultrasound • Quantitative serum β-hCG • Histologic evaluation of uterine contents
Management	• Dilation & suction curettage • Serial serum β-hCG post evacuation • Contraception for 6 months

COMPLETE
Vesicles Always Present
No Fetus
MORE Symptoms
VERY Higher HCG

PARTIAL
Vesicles NOT Always Present
Can have Fetus (NEVER viable)
LESS Symptoms
High HCG (but less than complete)

Normal HCG Level Peak

100,000 mIU/mL
12 weeks gestation

PROGNOSIS	
Benign	80%
Invasive (Persistent Trophoblastic Disease)	10 – 15%
Choriocarcinoma	2 – 3%
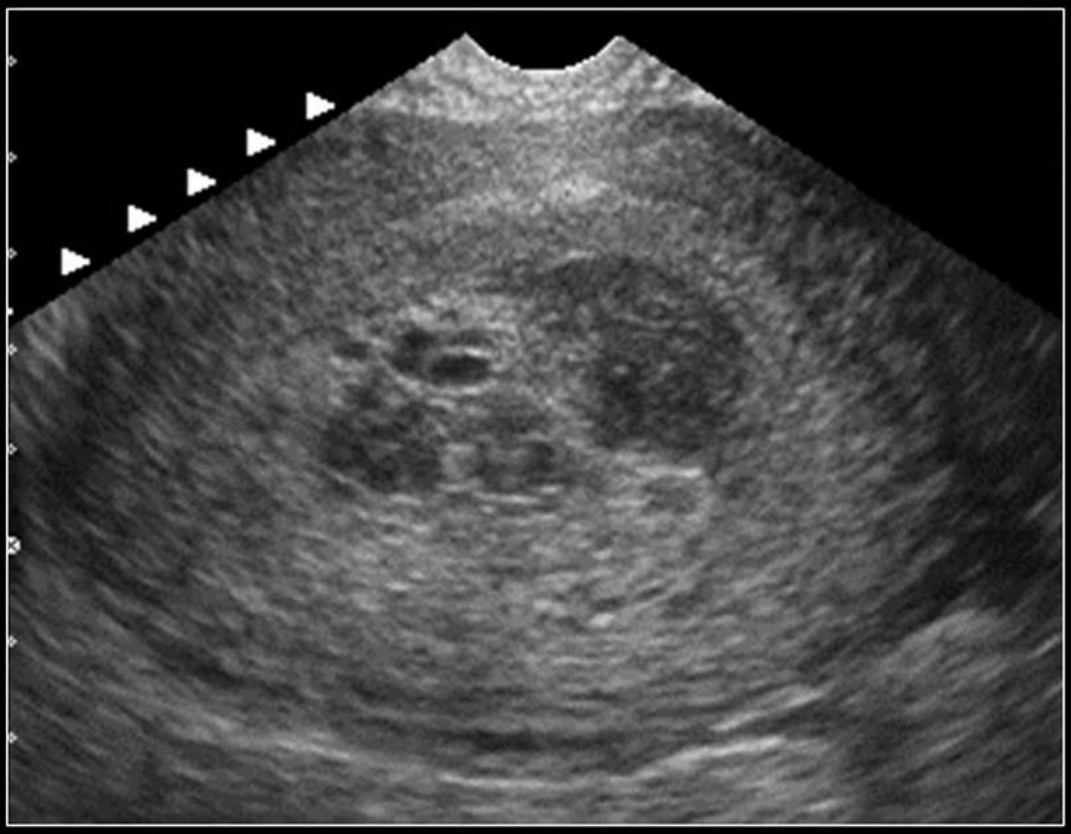
HYDROPIC VESICLES